



Emergency rescue stent grafting for a ruptured degenerated graft that bypassed coarctation of the aorta: a case report

Jin Ho Choi¹, Min Suk Choi², Haeyoung Lee³

¹Department of Thoracic and Cardiovascular Surgery, Daejeon Eulji University Hospital, Eulji University School of Medicine, Daejeon, Korea

²Department of Thoracic and Cardiovascular Surgery, Dongguk University Ilsan Hospital, Dongguk University School of Medicine, Ilsan, Korea

³Department of Thoracic and Cardiovascular Surgery, Kosin University Gospel Hospital, Kosin University College of Medicine, Busan, Korea

A 33-year-old man who had undergone bypass from the distal aortic arch to the proximal descending thoracic aorta with a Dacron graft to treat coarctation of the aorta 20 years prior presented to the emergency department with massive hemoptysis. He was diagnosed with a graft-to-bronchial fistula. After thoracic endovascular aneurysm repair through the coarctation, aortic replacement was performed 3 weeks later. Therefore, emergency-rescue thoracic endovascular aneurysm repair can be considered for preventing aortic rupture.

Keywords: Case reports; Coarctation of aorta; Dacron; Endovascular procedures; Ruptured aortic aneurysm

Introduction

In the literature, most late complications of Dacron grafts are anastomotic pseudoaneurysm, fistula, graft thrombosis, graft infection, or non-anastomotic aneurysmal change or rupture. Some reports on endovascular repair of Dacron graft dilatation with a subsequent anastomotic false aneurysm after post-coarctation aortic repair demonstrated the feasibility of endovascular treatment in selected candidates because it is not appropriate for all graft failure cases or for cases that require long-term follow-up for graft stability [1]. In this case, first of all we performed thoracic endovascular aneurysm repair (TEVAR) successfully to stabilize the patient's vital signs due to the risks associated with emergent aortic replacement.

Case

Ethical statements: This study was approved by the Institutional Ethics Committee of Daejeon Eulji University Hospital (EMC 2021-08-004). Informed consent was obtained from the patient.

A 33-year-old male patient was admitted with hemoptysis that measured about one liter. A bypass from the distal arch to the proximal descending thoracic aorta with a Dacron graft was achieved to treat coarctation of the aorta that had occurred 20 years prior. Additional bypass grafting from the right axillary to the femoral artery was performed 5 years

Received: December 3, 2021; **Accepted:** December 27, 2021

Corresponding Author: Haeyoung Lee, MD, PhD

Department of Thoracic and Cardiovascular Surgery, Kosin University Gospel Hospital, Kosin University College of Medicine, 262 Gamcheon-ro, Seo-gu, Busan 49267, Korea

Tel: +82-51-990-6466 Fax: +82-51-990-3066 E-mail: ansovinus0703@gmail.com

© 2022 Kosin University College of Medicine

© This is an Open Access article distributed under the terms of the Creative Commons Attribution Non-Commercial License (<https://creativecommons.org/licenses/by-nc/4.0/>) which permits unrestricted non-commercial use, distribution, and reproduction in any medium, provided the original work is properly cited.

after the initial procedure because of deterioration of coarctation. Hemoptysis originated from a graft-to-bronchial fistula, identified at a degenerative aneurysm of the Dacron graft. The diameter of the severely twisted graft on computed tomography (CT) scans was 20 mm (Fig. 1A). Although no interval change had been detected on scans obtained at 8 and 12 years, a CT scan in the emergency department revealed a diameter increase to 38 mm (Fig. 1B). TEVAR through coarctation and simultaneous extra-anatomic bypass grafting from the ascending to descending thoracic aorta were planned.

However, he presented at our hospital one day prior to admission for TEVAR due to massive hemoptysis. His medical condition was unstable. A follow-up CT scan showed increased graft size to 41 mm. We decided to perform an emergent TEVAR for coarctation of the aorta and aortic replacement when the patient's vital signs stabilized.

A 10-mm balloon angioplasty prior to TEVAR allowed the TEVAR catheter to pass the coarctation. After TEVAR using a Medtronic Valiant thoracic stent graft (22 mm in diameter, 150 mm in length; Medtronic Vascular, Santa Rosa, CA, USA) (Fig. 2A), hemoptysis was resolved. The

coarctation, however, was not sufficiently relieved, and the degree of dependence on the axillofemoral bypass graft increased. After 3 weeks of recovery from pneumonia and TEVAR, the final aortic replacement was implemented after the ruptured spot on the crisp graft was located (Fig. 1C, arrow). The aorta was replaced with a 22 mm Hemashield platinum woven double velour straight graft (Maquet Getinge Group, Rastatt, Germany) (Fig. 2B). Preoperative blood pressure was 131/63 mmHg in the right radial artery and 86/52 mmHg in the descending thoracic aorta, and the postoperative values were 122/70 mmHg and 110/69 mmHg, respectively.

The patient was discharged on postoperative day 10 without complications. Postoperative, 6-month follow-up CT scan showed no abnormality (Fig. 2C).

Discussion

This case report provides two significant insights: degenerative rupture of a Dacron graft and TEVAR as a therapeutic option for aortic rupture.

Previous reports indicated that most late complications

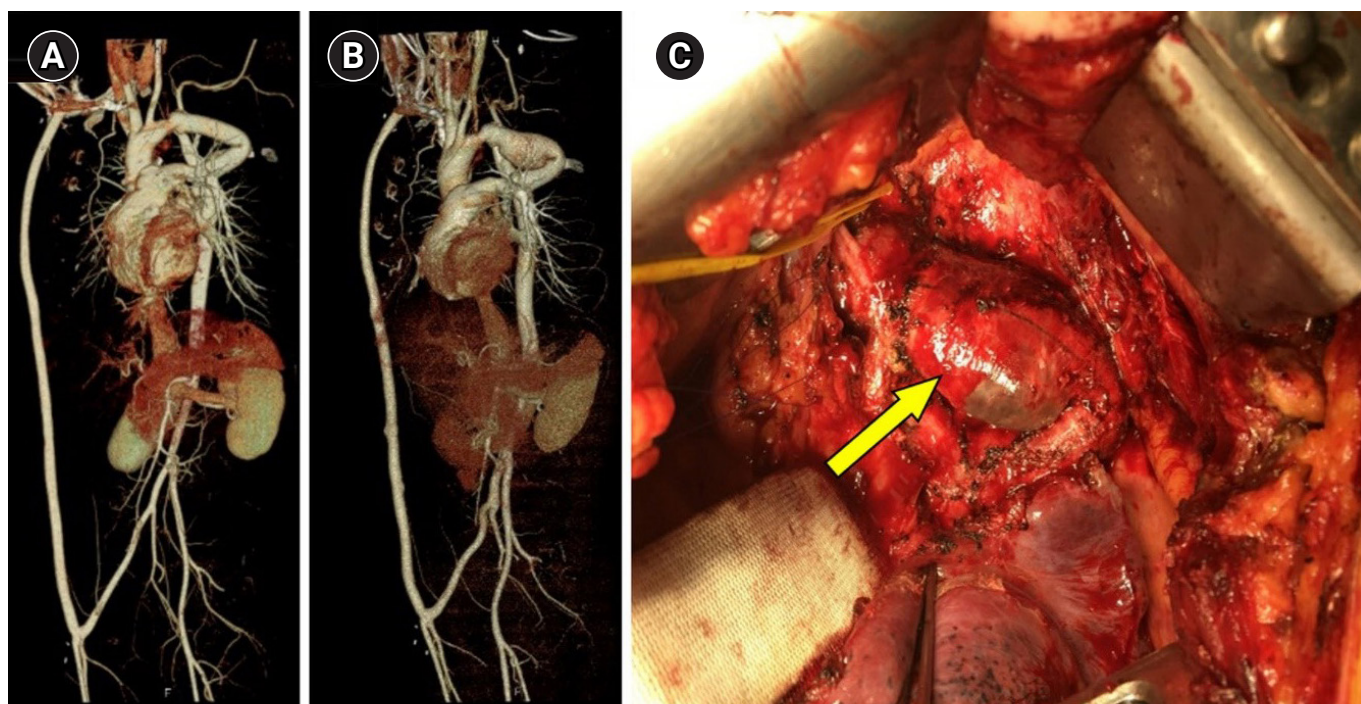


Fig. 1. Computed tomography scans from 8 years ago (A) and at presentation (B). Twisted graft with aneurysmal change at the rupture spot (arrow in C).

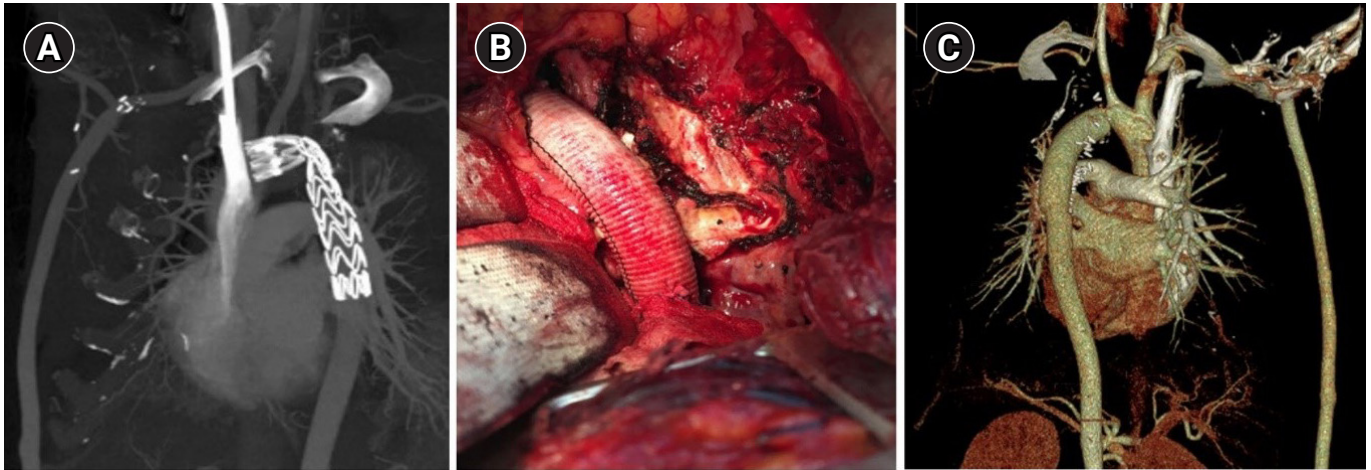


Fig. 2. Computed tomography (CT) scan after thoracic endovascular aneurysm repair, without any definite endoleak (A). The new Dacron graft in the operative findings (B) and a postoperative CT scan (C).

of Dacron grafts are anastomotic pseudoaneurysm, fistula, graft thrombosis, graft infection, or non-anastomotic aneurysmal change or rupture [1]. Complications associated with woven Dacron have been reported [2]. For this patient, the graft was in a twisted position for a long time, and the increase of afterload in the graft proximal to twisting resulted in gradual aneurysmal changes and, finally, graft rupture.

Previous reports on endovascular repair of Dacron graft dilatation with a subsequent anastomotic false aneurysm after post-coarctation aortic repair demonstrated the feasibility of endovascular treatment in select candidates; however, this approach is not appropriate for all graft failure cases or for cases that require long-term follow-up for graft stability [2].

In the present case, TEVAR was implemented to stabilize the patient's vital signs [3] due to the risks associated with emergent aortic replacement [4].

Recent reports have indicated that systolic pressure gradients were reduced significantly to 4 ± 6 mmHg after TEVAR [5]. In the present case, however, the systolic pressure gradient was 45 mmHg (131 mmHg vs. 86 mmHg), and the internal diameter was less than 10 mm. Therefore, the next aortic replacement was planned based on patient age, risk of progressive cardiac afterload or cerebral hypertension, and delayed complications of TEVAR.

Article information

Conflicts of interest

No potential conflict of interest relevant to this article was reported.

Funding

None.

Author contributions

Conceptualization: JHC, MSC, HL. Data curation: JHC, MSC, HL. Formal analysis: JHC, MSC, HL. Methodology: JHC, HL. Project administration: JHC, MSC, HL. Visualization: MSC. Writing-original draft: JHC, MSC, HL. Writing-review & editing: JHC, HL. Approval of final manuscript: JHC, MSC, HL.

ORCID

Jin Ho Choi, <https://orcid.org/0000-0001-9667-2343>

Min Suk Choi, <https://orcid.org/0000-0002-5482-1272>

Haeyoung Lee, <https://orcid.org/0000-0003-4972-3608>

References

1. Kawata M, Morota T, Takamoto S, Kubota H, Kitahori K. Non-anastomotic rupture in the guideline of a Dacron thoracic aortic graft. *J Vasc Surg* 2005;42:573.
2. Tomasi J, Belhaj Soulami R, Rolland M, Verhoye JP. Endovascu-

- lar repair of a Dacron pseudoaneurysm in an ascending-to-descending aortic bypass. *Aorta (Stamford)* 2020;8:104-6.
3. Lee Y, Kim GJ, Kim YE, Hong SW, Lee JT. Non-anastomotic rupture of a woven Dacron graft in the descending thoracic aorta treated with endovascular stent grafting. *Korean J Thorac Cardiovasc Surg* 2016;49:465-7.
 4. Di Bartolomeo R, Berretta P, Petridis FD, Folesani G, Cefarelli M, Di Marco L, et al. Reoperative surgery on the thoracic aorta. *J Thorac Cardiovasc Surg* 2013;145(3 Suppl):S78-84.
 5. Taggart NW, Minahan M, Cabalka AK, Cetta F, Usmani K, Ringel RE, et al. Immediate outcomes of covered stent placement for treatment or prevention of aortic wall injury associated with coarctation of the aorta (COAST II). *JACC Cardiovasc Interv* 2016;9:484-93.